

Thrombolysis of Occluded Femoropopliteal Graft with Locally Delivered Human Plasmin

Dragoslav Nenezić^{1,2}, Djordje Radak^{1,2}, Dario Jocić^{1,2}, Predrag Gajin^{1,2}, Slobodan Tanasković^{1,2}, Aleksandra Novaković³, Predrag Matic^{1,2}

¹Cardiovascular Institute "Dedinje", Belgrade, Serbia;

²School of Medicine, University of Belgrade, Belgrade, Serbia;

³Faculty of Pharmacy, University of Belgrade, Belgrade, Serbia

SUMMARY

Introduction Acute lower limb ischemia results from thrombosis or embolization of diseased native artery or previously implanted bypass graft. When this occurs, several options are available to restore blood flow: catheter-directed thrombolysis, mechanical thrombectomy or open surgery. Fundamental reasons to apply percutaneous interventions are avoiding open procedures in high risk patients, and avoiding difficult dissection through scar tissue.

Case Outline A 67-year-old male was admitted at our Institution for critical limb ischemia. After performed angiography the diagnosis of occluded femoropopliteal graft was established. Occlusion was resolved by catheter-directed thrombolysis with plasmin. Culprit lesions were treated by angioplasty.

Conclusion Our patient underwent a successful thrombolysis of occluded femoropopliteal graft with locally-delivered human plasmin.

Keywords: percutaneous intervention; catheter-directed thrombolysis; human plasmin; femoropopliteal bypass

INTRODUCTION

Peripheral artery occlusive disease is common and potentially serious problem. It is usually caused by atherosclerotic plaques which cause reduction of blood flow in lower extremities. It affects approximately 20% of adults older than 55 years, and increases significantly with age rising to 25%, among those over 80 years of age [1, 2].

Acute lower limb ischemia results from thrombosis or embolization of diseased native artery or previously implanted bypass graft. When such event occurs several options are available to restore blood flow: catheter-directed thrombolysis, mechanical thrombectomy or open surgery which is associated with higher morbidity and mortality compared with the first two methods of revascularization [3, 4].

Fundamental reasons to apply percutaneous interventions thus are avoiding open surgical procedures in high risk patients, and avoiding difficult dissection through scar tissue.

CASE REPORT

A 67-year-old male was admitted to our hospital due to critical limb ischemia. The patient was experiencing rest pain in the right foot with a sudden onset three days earlier. Past medical history included hypertension, dyslipidemia and heavy smoking. Three years prior to this hospitalization the patient underwent transluminal angioplasty and stenting of left iliac artery and redo right femoropopliteal above knee

bypass with a Dacron graft. Clinical examination revealed absent pulses distal from the right groin. Ankle-brachial index on admission on the right leg was 0. CT angiography (Figure 1) and color duplex scan confirmed occlusion of femoropopliteal bypass, and significant stenosis of right iliac artery. The popliteal artery was patent as were all three crural vessels.

After preparation, the patient was transferred to the Radiology Department. After puncturing contralateral common femoral artery, a guidewire was inserted and a six French sheath was placed. Heparin (10000 IU) was given intravenously. The stenotic right iliac artery was resolved by balloon angioplasty. A guidewire was advanced into the occluded femoropopliteal graft. A multi-side-hole infusion catheter (Angiodynamics Unifuse catheter, USA) was positioned into the thrombosed graft. Plasmin (Talecris Biotherapeutics, USA) infusion was started initially with pulse spray (1 ml per min, for 30 ml), for the initiation of thrombolysis, and continued for four and half hours of 45 ml of solution. Total dose of 150 mg (75 ml) of plasmin was administered. Follow-up angiography was performed after 2 hours and at the end of the treatment after 5 hours. Final angiography (Figure 2) revealed resolution of all intraluminal filling defects, and critical stenosis at the level of proximal and distal anastomosis of femoropopliteal bypass.

Former was resolved with stenting and latter by balloon angioplasty. There was no evidence of distal embolization. Double antiplatelet therapy, with aspirin and clopidogrel, was continued after intervention.

Correspondence to:

Predrag MATIĆ
Institut za kardiovaskularne
bolesti „Dedinje“
Heroja Milana Tepića 1
11000 Beograd
Srbija
pmpmatic@gmail.com

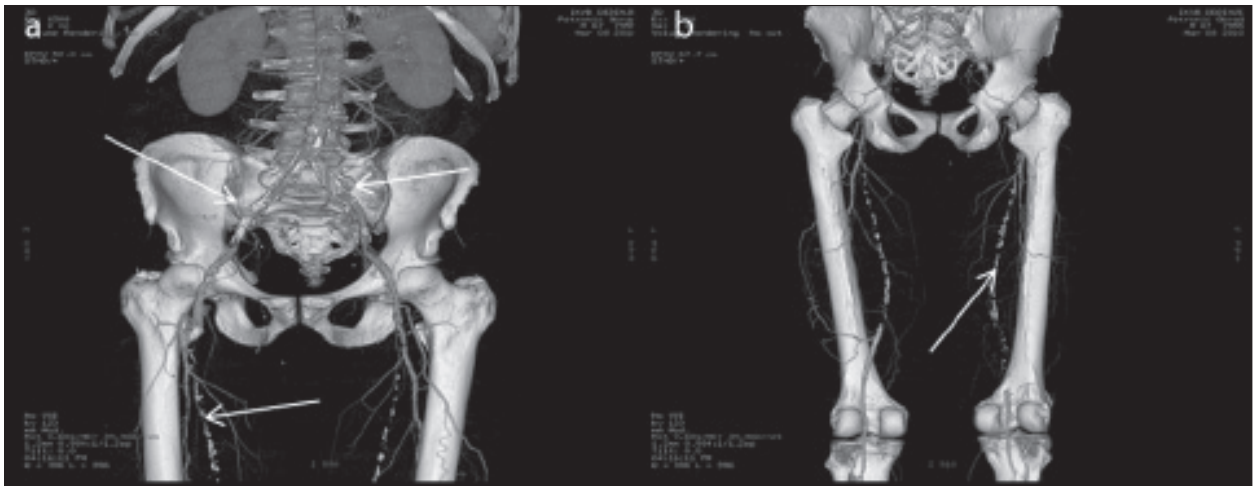


Figure 1. CT angiography before thrombolysis: a) anterior view on CT angiography – arrows showing stent in left common iliac artery; stenosis of right iliac artery; occluded femoropopliteal graft and heavily calcified and occluded native right superficial femoral artery; b) posterior view on CT angiography – arrow showing occluded femoropopliteal graft and heavily calcified and occluded native right superficial femoral artery.

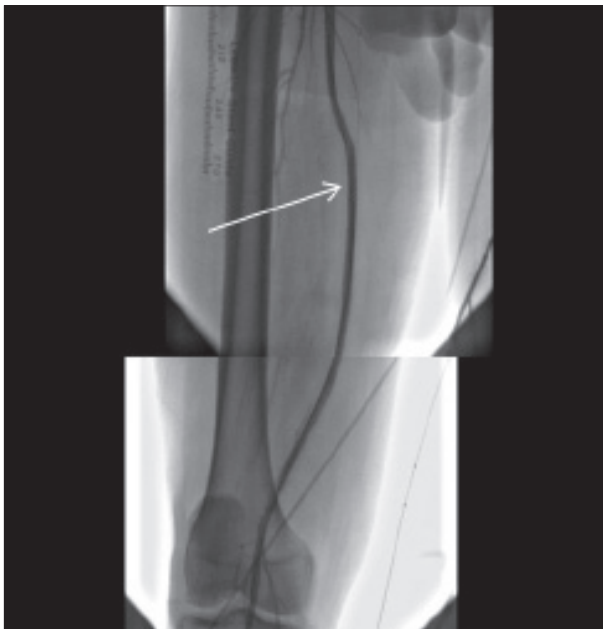


Figure 2. Arrow showing patent femoropopliteal graft after thrombolysis

Seven days later the patient was discharged with a patent graft and ankle-brachial index 1.0. One year follow-up showed full patency of femoropopliteal graft on CT angiography with patient leading normal life (Figure 3).

DISCUSSION

In past, several clinical studies have been conducted comparing the effects of locally delivered plasminogen activators (PA) with open surgery in the treatment of acute lower limb ischemia [5-8].

The Rochester trial [5] compared catheter-directed urokinase infusion with surgery for acute limb ischemia. During one year follow-up no difference was found in limb salvage between groups and mortality was significantly reduced with the urokinase group of patients. Bleeding complications were increased in the urokinase group compared to surgery.

The STILE trial (Surgery versus Thrombolysis for Ischemia of the Lower Extremity) [6] randomized patients to surgery or catheter-directed thrombolysis with

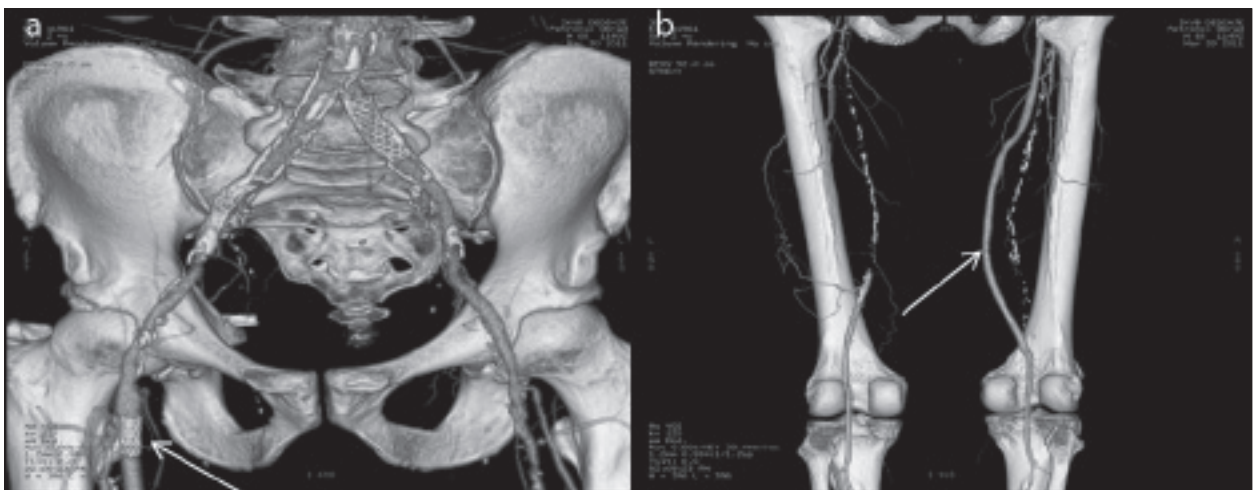


Figure 3. CT angiography after thrombolysis: a) anterior view on CT angiography – arrow showing stent in proximal anastomosis of patent femoropopliteal graft; b) posterior view on CT angiography – arrow showing patent femoropopliteal graft.

urokinase or recombinant tissue plasminogen activator, but it differed in that patients had acute (<14) and chronic (>14) limb ischemia. Intracranial hemorrhage occurred in 1.6% of patients, which is similar to the rate recorded in the TOPAS trial. A large benefit (fewer amputations, increase in amputation-free survival) was achieved for our patients with acute ischemia who were randomized to thrombolysis. However, the patients with chronic ischemia who were randomized to surgery experienced fewer amputations and improved amputation-free survival. These results were maintained at 1-year follow-up.

The TOPAS (Thrombolysis or Peripheral Arterial Surgery) [7, 8] trial randomized patients to recombinant urokinase or surgery, but found no difference in amputation rate (15% vs. 13%) or in amputation-free survival at six months and one year respectively (20% vs. 17%). Bleeding complications, however, were significantly increased in patients randomized to urokinase therapy.

Results from randomized clinical trials suggest that thrombolytic therapy is superior to surgery for treatment of acute (less than 14 days) occlusions regarding bypass graft occlusions and long occlusions without adequate run-off vessel suitable for surgical bypass. However, open surgery should be recommended for subacute or chronic occlusions and in native arteries occlusions [9].

Currently held opinions on the role of catheter-based thrombolysis therapy in the patients with acute leg ischemia, can be considered as complementary with surgical or percutaneous revascularization with an acceptably low complication rate [10, 11].

The goal of catheter-directed intra-arterial thrombolysis is to eliminate occluding thrombus and restore native artery or bypass graft patency. In that way the underlying lesion is revealed and could be treated by angioplasty thus avoiding open surgery and reducing morbidity and mortality [12].

It has been shown that systemic infusion of plasminogen activators is ineffective when compared to catheter-directed intra-thrombus infusion [13, 14]. Catheter-directed thrombolysis provides maximal delivery of agent to a thrombus, thus improving the degree of thrombolysis [15, 16].

The fibrinolytic system is based upon conversion of an inactive pro-enzyme plasminogen, to active form plasmin by plasmin activators. Physiologic dissolution of thrombus occurs by plasmin action on fibrin [17]. Free plasmin is inactivated rapidly by plasma alpha-2-antiplasmin, a naturally occurring protease inhibitor. This results in both a decrease in plasmin production and a decrease in the dissolution of fibrin clots [18]. But when bound to a thrombus, plasmin is protected from inhibition [19], thereby allowing an effective thrombolysis.

The limitations of plasminogen activators (PA) usage is that they are released systemically even when delivered

locally by catheter. This increases a bleeding risk because fibrinolysis is activated at sites of remote vascular injury or malformation [20]. The most severe hemorrhagic complication of catheter-delivered PA is intracranial hemorrhage, occurring in 1-2.8% of patients [21, 22, 23] and higher, correlated with poor hypertensive control [24].

Different studies have suggested that the use of urokinase may be associated with a lower incidence of hemorrhagic complications compared to recombinant tissue plasminogen activator (rtPA) [9].

However, in 2010 Cochrane systematic review stated that the incidence of bleeding complications was not statistically significantly greater with rtPA than with other regimens [20].

The other drawback of PA use is that they need plasminogen in order to express action. Since thrombus-associated plasminogen may be present in limited supply [25], it can result in suboptimal lysis of retracted thrombi and incomplete reperfusion of occluded vessels.

On the contrary, human plasmin biochemistry is favorable because it is rapidly and irreversibly inhibited by alpha-2-antiplasmin and it is a direct-acting fibrinolytic [25, 26] not requiring plasminogen to achieve fibrinolysis. The physiologic relevance of these attributes of plasmin is supported by animal studies [26]. Experimental data indicate that we should recognize plasmin as viable, even preferable thrombolytic agent. The most recent pre-clinical studies and reports confirm that plasmin has marked hemostatic safety advantage over t-PA, and superior-thrombolytic efficiency, when delivered by catheter to occluded arteries [27-31].

After more than 50 years, the field has come full circle, and plasmin as the thrombolytic agent and catheter use for local delivery of agent may represent a step forward in thrombolytic therapy compared to PA [32].

Marder [33] proposed that locally-delivered plasmin could also have a significant role in the treatment of deep vein thrombosis due to its safety and efficacy compared to PA.

First-in-human experiences with locally administered plasmin were gained by Shlansky-Goldberg et al. [27, 34] in the study where thrombosed synthetic hemodialysis access grafts were treated for occlusion. The overall conclusion of this Phase I study was that human plasmin was safe and well tolerated in the hemodialysis graft occlusion subject population, and showed a dose response thrombolytic trend.

Our patient was a part of Phase I PRIORITY (Plasmin Revascularization for the Ischemic Lower Extremity) study - the first human dose-escalation trial of plasmin in patients with acute limb ischemia. Although successful in our case, we should wait end of the study to obtain more valid conclusions.

REFERENCES

- Hankey GJ, Norman PE, Eikelboom JW. Medical treatment of peripheral arterial disease. *JAMA*. 2006; 295(5):547-53.
- Ng EL, Weiland TJ, Jelinek GA, Hadgkiss E, Wilson A. Prevalence of and risk factors for peripheral arterial disease in older adults in an Australian emergency department. *Vascular*. 2014; 22(1):1-12.
- Norgren L, Hiatt WR, Dormandy JA, Nehler MR, Harris KA, Fowkes FG, et al. Inter-Society Consensus for the Management of Peripheral Arterial Disease (TASC II). *Eur J Vasc Endovasc Surg*. 2007; 33(Suppl 1):S1-75.
- Norgren L, Hiatt WR, Dormandy JA, Nehler MR, Harris KA, Fowkes FG, et al. Inter-Society Consensus for the Management of Peripheral Arterial Disease. *Int Angiol*. 2007; 26(2):81-157.
- Ouriel K, Shortell CK, DeWeese JA, Green RM, Francis CW, Azodo MVU, et al. A comparison of thrombolytic therapy with operative revascularization in the initial treatment of acute peripheral artery ischemia. *J Vasc Surg*. 1994; 19:1021-30.
- The STILE Investigators. Results of a prospective randomized trial evaluating surgery versus thrombolysis for ischemia of the lower extremity. The STILE trial. *Ann Surg*. 1994; 220:251-66.
- Ouriel K, Veith FJ, Sasahara AA. Thrombolysis or Peripheral Arterial Surgery: phase I results. TOPAS investigators. *J Vasc Surg*. 1996; 23:64-75.
- Ouriel K, Veith FJ, Sasahara AA. A comparison of recombinant urokinase with vascular surgery as initial treatment for acute arterial occlusion of the legs. Thrombolysis or Peripheral Arterial Surgery (TOPAS) Investigators. *N Engl J Med*. 1998; 338:1105-11.
- Karnabatidis D, Spiliopoulos S, Tsetis D, Siablis D. Quality improvement guidelines for percutaneous catheter-directed intra-arterial thrombolysis and mechanical thrombectomy for acute lower-limb ischemia. *Cardiovasc Intervent Radiol*. 2011; 34:1123-36.
- Camerota AJ, Gravett MH. Do randomized trials of thrombolysis versus open revascularization still apply to current management: what has changed? *Semin Vasc Surg*. 2009; 22(1):41-6.
- Van den Berg JC. Thrombolysis for acute arterial occlusion. *J Vasc Surg*. 2010; 52(2):512-15.
- Kashyap SV, Gilani R, Bena FJ, Bannazadeh M, Sarac PT. Endovascular therapy for acute limb ischemia. *J Vasc Surg*. 2011; 53:340-46.
- Simpson D, Siddiqui MA, Scott LJ, Hilleman DE. Spotlight on reteplase in thrombotic occlusive disorders. *BioDrugs*. 2007; 21(1):65-8.
- Lippi G, Mattiuzzi C, Favaloro EJ. Novel and emerging therapies: thrombus-targeted fibrinolysis. *Semin Thromb Hemost*. 2013; 39(1):48-58.
- Limtungturakul S, Wongprapuarut N, Pornratanarangsri S, Tresukosol D, Ruansetakit C, Mutirangura P, et al. Early experience of catheter directed thrombolysis for acute limb ischemia of native vessels and bypass graft thrombosis in Thai patients. *J Med Assoc Thai*. 2011; 94(Suppl 1):S11-8.
- Wicky S, Pinto EG, Oklu R. Catheter-directed thrombolysis of arterial thrombosis. *Semin Thromb Hemost*. 2013; 39(4):441-5.
- Novoknatny V. Structure and activity of plasmin and other direct thrombolytic agents. *Thromb Res*. 2008; 122(Suppl 3):S3-8.
- Fortenberry YM. Plasminogen activator inhibitor-1 inhibitors: a patient review (2006-present). *Expert Opin Ther Pat*. 2013; 23(7):801-15.
- Wiman B, Lijnen HR, Collen D. On the specific interaction between the lysine-binding sites in plasmin and complementary sites in alpha 2-antiplasmin and in fibrinogen. *Biochim Biophys Acta*. 1979; 579:142-54.
- Robertson I Kessel DO, Berridge DC. Fibrinolytic agents for peripheral arterial occlusion. *Cochrane Database Syst Rev*. 2010; (3):CD001099.
- Marder VJ, Stewart D. Towards safer thrombolytic therapy. *Sem Hematol*. 2002; 39:206-16.
- Quriel K, Kandarpa K. Safety of thrombolytic therapy with urokinase of recombinant Tissue plasminogen activator for peripheral arterial occlusion. *J Endovasc Ther*. 2004; 11:436-46.
- Lyden PS. Endovascular treatment of acute limb ischemia: Review of current plasminogen activators and mechanical thrombectomy devices. *Perspect Surg Endovas Ther*. 2010; 22(4):219-22.
- Agle SC, McNally MM, Powell CS, Bogey WM, Parker FM, Stoner MC. The association of periprocedural hypertension and adverse outcomes in patients undergoing catheter-directed thrombolysis. *Ann Vasc Surg*. 2010; 24(5):609-14.
- Camerota AJ. Development of catheter-directed intrathrombus thrombolysis with plasmin for the treatment of acute lower extremity arterial occlusion. *Thromb Res*. 2008; 122(Suppl 3):S20-6.
- Marder VJ. Pre-clinical studies of plasmin: superior benefit-to-risk ratio of plasmin compared to tissue plasminogen activator. *Thromb Res*. 2008; 122(Suppl 3):S9-S15.
- Shlansky-Goldberg R. Phase 1 study of human plasma-derived plasmin (TAL-05-00018) in haemodialysis graft occlusion. *Thromb Res*. 2008; 122(Suppl 3):S16-9.
- Marder VJ, Jahan R, Gruber T, Goyal A, Arora V. Thrombolysis with plasmin: implications for stroke treatment. *Stroke*. 2010; 41(10 Suppl):S45-9.
- Marder VJ, Blinc A, Gruber T, Tratar G, Sabovic M, Starkman S, et al. Comparison of plasmin with recombinant tissue-type plasminogen activator in lysis of cerebral thromboemboli retrieved from patients with acute ischemic stroke. *Stroke*. 2011; 42(8):2222-8.
- Marder VJ, Comerota AJ, Shlansky-Goldberg RD, Davis JP, Deng C, Hanna K, et al. Safety of catheter-delivered plasmin in patients with acute lower extremity arterial or bypass graft occlusion: phase I results. *J Thromb Haemost*. 2012; 10(6):985-91.
- Yerhamme P, Heye S, Peerlinck K, Cahillane G, Tangelder M, Fourneau I, et al. Catheter-directed thrombolysis with microplasmin for acute peripheral arterial occlusion (PAO): an exploratory study. *Int Angiol*. 2012; 31(3):289-96.
- Marder VJ. Historical perspective and future direction of thrombolysis research: the re-discovery of plasmin. *J Thromb Haemost*. 2011; 9(1):364-73.
- Marder VJ. Thrombolytic therapy for deep vein thrombosis: potential application of plasmin. *Thromb Res*. 2009; 123(Suppl 4):S56-61.
- Shlansky-Goldberg R, Matsumoto AH, Baumbach GA, Siegel JB, Raabe RD, Murphy TP, et al. A first-in-human phase I trial of locally-delivered human plasmin for hemodialysis graft occlusion. *J Thromb Haemost*. 2008; 6(6):944-50.

Тромболиза оклудираниог феморопеплитеалног графта локално примењеним хуманим плазмином

Драгослав Ненезић^{1,2}, Ђорђе Радак^{1,2}, Дарио Јоцић^{1,2}, Предраг Гајин^{1,2}, Слободан Танасковић^{1,2}, Александра Новаковић³, Предраг Матић^{1,2}

¹Институт за кардиоваскуларне болести „Дедиње“, Београд, Србија;

²Медицински факултет, Универзитет у Београду, Београд, Србија;

³Фармацеутски факултет, Универзитет у Београду, Београд, Србија

КРАТАК САДРЖАЈ

Увод Ишемија доњих екстремитета је последица тромбозе или емболизације оболеле нативне артерије или имплантираног графта. Постоји неколико начина лечења ишемије: тромболиза катетером, механичка тромбектомија и хируршко лечење. Основни разлози за примену перкутаних интервенција јесте избегавање класичног хируршког лечења код болесника с високим ризиком, као и избегавање препарисања крвног суда у оžilку.

Приказ болесника Мушкарац стар 67 година примљен је

у болницу због критичне ишемије доњих екстремитета. По учињеној ангиографији дијагностикована је тромбоза феморопеплитеалног графта. Оклузија је решена применом плазмина уз употребу интраартеријског катетера. Стенозе које су откривене после тромболизе лечене су ангиопластиком.

Закључак Тромболизом уз примену плазмина и интраартеријског катетера успешно је излечена оклузија феморопеплитеалног графта.

Кључне речи: перкутане интервенције; тромболиза катетером; хумани плазмин; феморопеплитеални графт

Примљен • Received: 29/05/2013

Прихваћен • Accepted: 07/10/2013