

Beneficial effects of dimethyl sulfoxide on tungstates hepatoprotective activity

**Snežana Uskoković-Marković^{1*}, Marina Milenković²,
Aleksandra Topić³, Jelena Kotur-Stevuljević³,
Aleksandra Stefanović³, Jelena Antić-Stanković²,
Ivanka Holclajtner-Antunović⁴**

¹Department of Analytical Chemistry,

²Department of Microbiology and Immunology,

³Department of Medical Biochemistry,
Faculty of Pharmacy, University of Belgrade,
Vojvode Stepe 450, Belgrade 11 221, Serbia

⁴Faculty of Physical Chemistry, University of Belgrade,
Studentski trg 12-16, Belgrade, Serbia

Summary

Tungstates and polyoxotungstates have been known to be bioactive compounds for a long time. Based on our previous work about sodium tungstate (ST) and 12-tungstophosphoric acid (WPA) as hepatoprotective agents, we performed a seven week long experiment in rats, using ST and WPA pretreatments in thioacetamide (TAA) induced acute liver necrosis. The possible influences of dimethyl sulfoxide (DMSO), given orally for 3 consecutive days before inducing hepatic lesions, were also investigated. The effects were evaluated by the activity of serum enzymes, oxidative stress parameters, antioxidative defense markers, and histopathology in Wistar rats. The obtained results suggest that oral pretreatment with tungstates, especially ST, in combination with DMSO, before the TAA induced liver necrosis, could be useful for the prevention of hepatic injury in rats.

Key words: Dimethyl sulfoxide; tungstates; liver necrosis, rats

*Corresponding Author: Snežana Uskoković-Marković, email: snezaum@pharmacy.bg.ac.yu

Introduction

Polyoxometalates (POMs) are a huge heterogenic group of compounds interesting for both theoretical and practical investigations. Their applications are based on their physico-chemical properties, such as structure, electron and proton transfer/storage abilities, thermal stability, and high Bronsted acidity, which make them very applicable catalysts, superionic proton conductors, nanomaterials, reagents in analytical chemistry, and in recent time, as bioactive compounds (1-4).

Polyoxometalates of Keggin type (Fig. 1), such as 12-tungstophosphoric acid (WPA), are compounds with a potent bioactivity (5,6). Three decades ago it was confirmed that WPA affects mitochondrial respiration, and at high concentrations, solubilises mitochondrial proteins (7). Polytungstophosphates were also shown to interact with NADPH oxidase and dehydrogenase, as well as with succinoxidase and influence phosphorus-ATP exchange activity in isolated mitochondria (8).

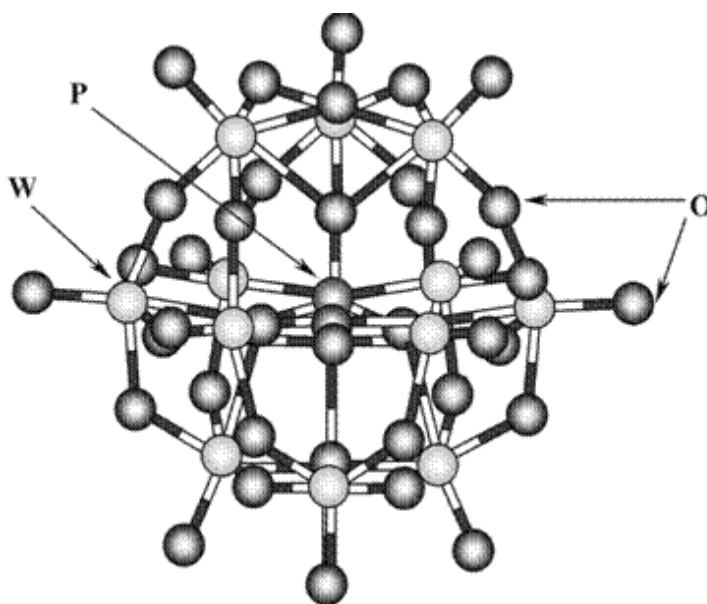


Fig.1. Structure of WPA presented as Keggin anion, $[PW_{12}O_{40}]^{3-}$

Among the many investigated compounds which could be able to protect liver against injury produced by drugs and chemicals is dimethyl sulfoxide (DMSO). An aprotic solvent, DMSO is well established compound which protects the liver against injury produced by carbon tetrachloride (CCl₄) (9) and thioacetamide (TAA) (10) when it is administrated *prior to or concomitantly* with the toxicant. DMSO has several physiological actions that contribute to its protective effects, such as enhancement of organ blood flow, anti-inflammatory activity, and *reactive oxygen species* (ROS) scavenging (11). In evaluating a number of known hepatoprotective agents for their protective roles, it was found that DMSO inhibits cytochrome P450 isoenzymes (12).

Since 1978, DMSO was approved by the United States Food and Drug Administration (FDA) for treatment of interstitial cystitis (13) and till nowadays a wide range of pharmacological effects exerted by DMSO has been documented. The anti-inflammatory properties of DMSO has justified its use for the treatment of inflammatory diseases (scleroderma, osteoarthritis, and rheumatoid arthritis) (14), as well as for the treatment of gastrointestinal and dermatologic diseases (15,16), some manifestations of amyloidosis (17) and brain edema (18).

This work is based on our previously published results (19) about the interactions of polytungstophosphate (represented by WPA) and tungstate with hepatic tissue and their possible protective roles against hepatic lesions produced by TAA and CCl₄ in adult rats. Since by increasing the pH value of a WPA solution to more physiological-like values, depending on the acidity, this compound gets transformed into numerous forms to afford tungstate and phosphate as final hydrolysis products, it is worth to fully investigate the effects of sodium tungstate (ST) and WPA at the same time. The aim of this study was to investigate possible synergistic effects of DMSO as a compound with proven protective role (20), combined with ST and WPA against hepatic necrosis produced by TAA in adult Wistar rats. Doses of ST, WPA and DMSO for this study were chosen according to literature data (19, 20).

Materials and methods

Animals and induction of liver necrosis

Female Wistar rats (weighing 150-180 g) were purchased from the Military Medical Academy Animal House, Belgrade. They were housed in a local animal house with controlled light cycle and were given commercial food pellets and water *ad libitum*. To evaluate and compare the protective roles of WPA and ST against hepatic lesions produced by TAA, they were daily administrated to rats orally for 7 weeks (50 mg/kg b.w., dissolved in a saline

solution prior to use, 200 μ L) while DMSO was given orally (4.0 g/kg b.w.) for 3 consecutive days before inducing hepatic lesions by TAA. Acute liver necrosis was induced by administering a single intraperitoneal (i.p.) injection of 400 mg/kg b.w. of TAA dissolved in a saline solution. Nine experimental groups were created: N- healthy control rats; T- rats treated with TAA; WPA- rats treated with WPA; ST- rats treated with ST; D+T- rats treated with DMSO before TAA induced necrosis; WPA+T- rats pretreated with WPA before TAA induced necrosis; ST+T- rats pretreated with ST before TAA induced necrosis; WPA+D+T- rats pretreated with WPA and DMSO before TAA induced necrosis and ST+D+T- rats pretreated with ST and DMSO before TAA induced necrosis. Each group contained ten rats. Animal studies were conducted in accordance with the institutional guidelines for care and use of laboratory animals.

Chemicals

Chemicals used in this study were of the highest purity. WPA was synthesized according to the Drachels method (21) and recrystallized twice from bidistilled water. ST was administered as Na₂WO₄ · 2H₂O (Aldrich Chemical Company, Milwaukee, USA). Other chemicals and solvents (H₃PO₄, HCl, diethyl ether), were of commercial p.a. reagent-grade, used without any other purification procedure.

Histopathology

Hepatic morphology was assessed by light microscopy. The left lateral lobe of the liver was sliced (three slices per rat) fixed in 10% buffered-neutral formalin and embedded in paraffin. Transverse sections of 5 μ m in thickness were subjected to hematoxylin and eosin (H&E) staining before examinations. The sections were scanned and analyzed by a certified pathologist who was not aware of sample assignment to experimental groups. A minimum of 10 fields was scored per liver slice to obtain the mean value. Extents of liver necrosis, hepatocyte degeneration, and portal inflammation were graded using an arbitrary scale: 0- negative findings (0%); 1- slight (about 20-30% necrosis); 2: moderate (about 50% necrosis); 3: marked (about 75% necrosis); and 4: very intense (about 90-100% necrosis) (22).

Processing of the liver tissue and biochemical estimations

Liver injury was evaluated by analyzing serum and liver tissue lysate obtained from rats sacrificed 24^h after receiving the necrogenic dose of TAA. Rats were anesthetized with ether and the blood was drawn by puncture from vena cava inferior. Blood was allowed to clot and the serum was separated by centrifugation 1200 x g for 10 min. Serum was used to analyze activity of liver

enzymes alkaline phosphatase (AP), alanine transaminases (ALT) and aspartate transaminase (AST). Other biochemical estimations were performed on a tissue homogenate prepared from the liver.

Total liver weight of rats from each group was also recorded before the tissue was processed for analyses. The livers of the rats were removed, washed in ice-cold saline solution, blotted and a small portion was cut and weighed for homogenization. Tissue lysate was prepared in nine volumes of 0.1 M phosphate buffer (pH 7.4) containing 1.15% KCl, using a homogenizer. A portion of the homogenate was kept for determination of hepatic malondialdehyde and reduced glutathione content. The rest of the homogenate was subjected to centrifugation in a cooling centrifuge initially at 800 x g for 10 min and the supernatant was centrifuged at 9500 x g for 20 min to get the post-mitochondrial supernatant (used to measure activity of xanthine oxidase).

Activity of alanine transaminase, aspartate transaminase and alkaline phosphatase was measured using diagnostic kits (Randox Laboratories, UK).

To determine the index of oxidative stress in the liver tissue, we used the thiobarbituric acid reacting substances (TBARS) test that measures the quantity of the malondialdehyde (MDA)-TBA 1:2 adduct, according to Girotti et al. (23).

The rate of nitroblue tetrazolium reduction was used to measure the level of superoxide anion (O_2^-), as a marker of the first stage of oxidative stress, described by Auclair and Voisin (24).

Reduced glutathione (GSH) content, as an indicator of antioxidative defence status, was measured according to method of Jollow et al. (25).

Xanthine oxidase (XO) in postmitochondrial supernatant (PMS) was assayed according to Stirpe-DellaCorte method (26). The total protein concentration in all tissue samples was assayed according to Bradford's method (27).

Statistical analysis

All data were expressed as mean \pm standard error of mean (S.E.M). Differences between groups treated alone by hepatotoxic agent and all the other experimental groups were assessed by the Mann-Whitney *U*-test and $P < 0.05$ was considered to be significant.

Results and discussion

Histopathology

Histopathology was done to substantiate the biochemical findings. Sections from the control (saline injected) rats exhibited normal lobular architecture with central vein and radiating hepatic cords (Fig. 2a). Histological examination showed that hepatic cell death induced by TAA is restricted to necrosis. Apoptotic bodies were not detected in any of the slides. Severe centrilobular congestion, massive necrosis, and mononuclear cell infiltration were observed in TAA treated rats. The sinusoids between the hepatic cells, the central and portal veins were markedly dilated. These changes were almost absent (except for a few necrotic areas) in rats receiving ST+DMSO and WPA+DMSO followed by TAA (Fig. 2c,d). The histological examination of liver of WPA+D+T and ST+D+T treated groups showed less necrosis and less inflammation. The infiltration of inflammatory cells into the liver that occurs with injury is also known to contribute to further progression of the injury. DMSO can decrease the recruitment, chemotaxis, and activation of inflammatory cells.

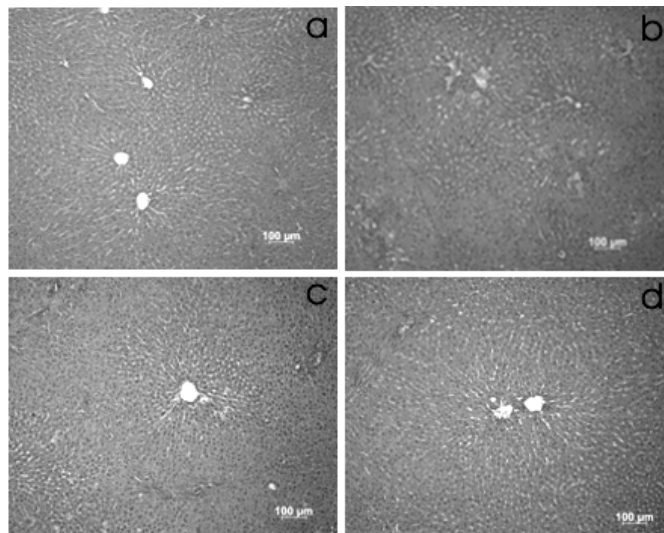


Fig.2. The representative hepatic histopathology and liver necrosis score.
(a) Normal liver from healthy control rat.
(b) Severe centrilobular necrosis and infiltration. Rats treated with TAA.
(c) Rats treated with ST+ DMSO + TAA.
(d) Rats treated with WPA +DMSO +TAA. Hematoxylin and Eosin (H&E) staining (100x).

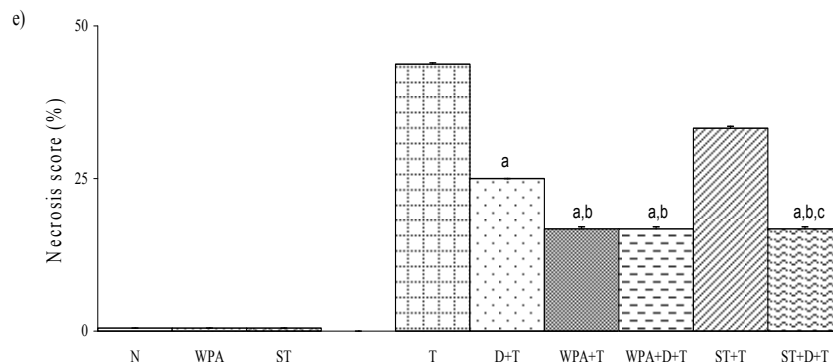


Fig. 2. The representative hepatic histopathology and liver necrosis score. (e) Necrosis score (%) of investigated groups. Data are expressed as means \pm S.E.M. (n=10). ^a different from T group; ^b different from D+T group; ^c different from WPA+T or ST+T groups.

Biochemical parameters

The serum activities of ALT, AST and AP were used as biochemical markers for the early acute hepatic damages. Effects of WPA-, ST-, and DMSO-pretreatment on parameters of TAA-induced liver necrosis are presented at Fig. 3. The levels of these enzymes in TAA-treated rats were significantly higher than in normal control (Fig. 3). In WPA and ST treated rats the activity of these parameters was not different according the untreated rats. WPA- pretreatment in TAA-induced necrosis showed a great decrease of liver enzymes. The significant decrease of parameters of necrosis was in WPA-pretreated rats as well as in WPA+D and ST+D, while DMSO-pretreatment and ST were not efficient in decreasing necrosis parameters (Fig. 3a-c).

The results of oxidative stress parameters (activity of xanthine oxidase, level of superoxide anion and level of malondialdehyde) and antioxidative defense (reduced glutathione) in the liver homogenate in all treated groups is shown in Fig. 4.

In WPA- and ST- treated rats the activity of xanthine oxidase was not different comparing to the untreated rats (Fig. 4a). In TAA-treated rats, XO was elevated. The activity of XO in WPA-, WPA+D- and ST+D- pretreatment in TAA-induced necrosis was significantly decreased. In both, DMSO- and ST-pretreatment, activity of XO was not decreased.

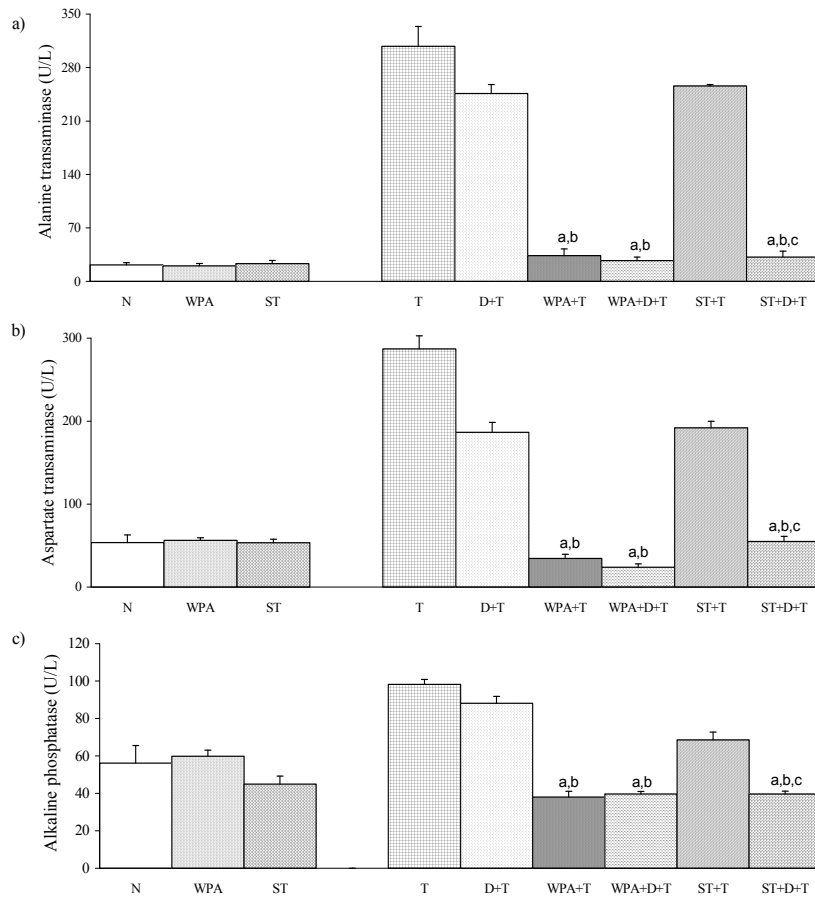


Fig 3. Effects of WPA-, ST-, and DMSO-pretreatment on parameters of TAA-induced liver necrosis on: a) activity of AST (U/L); b) activity of ALT (U/L); c) activity of AP (U/L). Data are expressed as means \pm S.E.M. (n=10). ^a different from T group; ^b different from D+T group; ^c different from WPA+T or ST+T groups.

To investigate oxidative stress in the liver after administration of hepatotoxic agent and protective roles of the two forms of tungsten, we measured the level of superoxide anion radical ($O_2^{\cdot-}$) and malondialdehyde (MDA), Fig. 4b and 4c, respectively. Increase of oxidative stress parameters, $O_2^{\cdot-}$ and MDA was significant in both treated groups. All pretreatments showed significant decrease in the level of $O_2^{\cdot-}$, while MDA was significantly decreased only in the WPA+D-pretreated group.

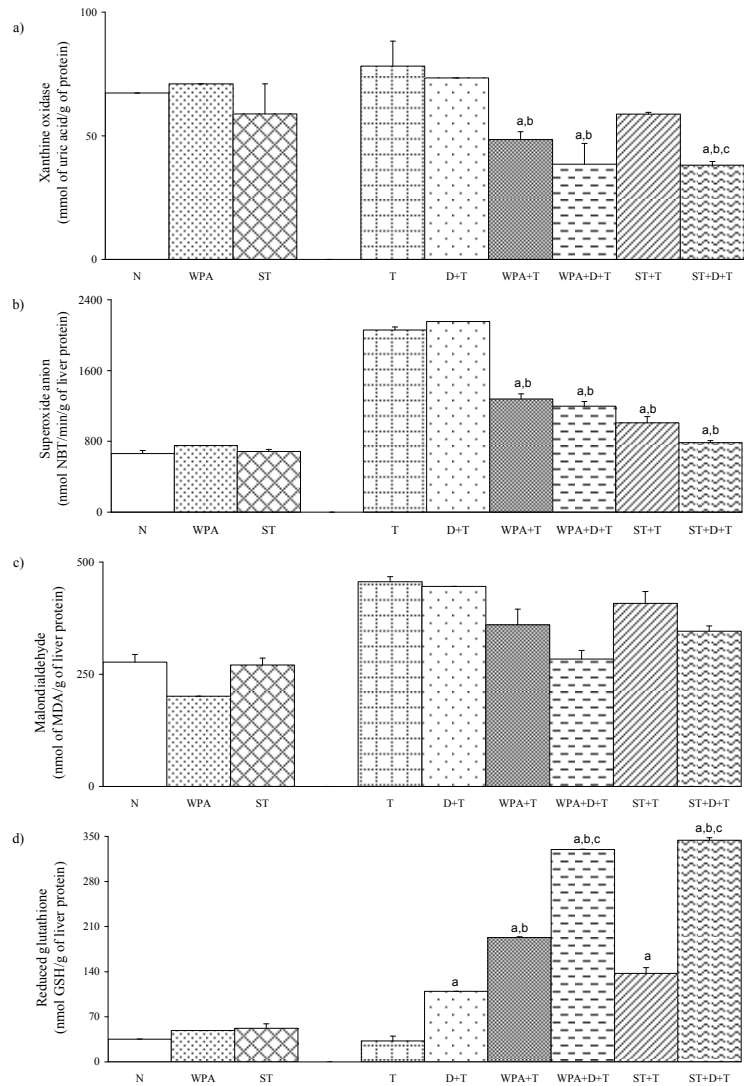


Fig 4. Effects of WPA-, ST-, DMSO-pretreatment on oxidative stress parameters and antioxidative defense status after administration of TAA on: a) activity of XO (mmol uric acid/g of protein); b) level of superoxide anion (nmol NBT/min/g of liver protein); c) malondialdehyde (nmol MDA/g of liver protein); d) Reduced glutathione (nmol GSH/g of liver). Data are expressed as means \pm S.E.M (n=10). ^a different from T group; ^b different from D+T group; ^c different from WPA+T or ST+T groups.

Significant decrease of reduced glutathione (GSH) was detected in TAA-treated rats (Fig. 4c) as the result of an effort by the liver to neutralize the effect of ROS produced by TAA. Pretreatments with tungstates, followed by TAA administration, lead to significant rise in hepatic GSH level, for both forms of tungstates. Greater elevation of GSH was found in WPA+D-, ST+D-pretreated groups than in WPA- and ST- pretreated groups. As expected, DMSO-pretreatment was not effective in elevation of GSH.

The present study was designed to evaluate whether pretreatment with different compounds of tungstate (WPA and ST) would have a hepatoprotective effect on chemically induced liver necrosis. One of them, ST, was previously studied and it was proven that compound could prevent progression of CCl₄- and TAA- induced hepatic injury (14). However, the *in vivo* hepatoprotective activity of WPA remains unknown. Supplementation of rats with WPA or with ST during the 7 weeks was safe and did not cause any changes of tested liver enzymes, and histopathological examinations have shown no sign of damage (Fig. 2.) when compared to the untreated control. The necrogenic doses of TAA which were given to rats significantly elevated the liver enzyme (Fig. 3) and necrosis scores (Fig. 2e).

Histopathological data also point towards beneficial effects of WPA and ST in ameliorating liver damage induced by TAA (Fig. 2). ST-pretreatment alone has no hepatoprotective properties. Further, we did not obtain that pretreatment with DMSO during the three consecutive days before induction of liver necrosis has a protective effect, but when DMSO was applied after WPA- and ST- pretreatment, alleviation in liver injury was observed, especially for ST. TAA is a thiono-sulfur-containing compound which metabolizes to acetamide and thioacetamide-S-oxide by the mixed function oxidase system. The cytochrome P450 system further metabolizes thioacetamide-S-oxide to reactive thioacetamide-S-dioxide, which is capable of binding to tissue macromolecules. TAA mediates its toxicity via the formation of free radicals, especially ROS, which interact with the membrane unsaturated lipids, consequently promoting lipid peroxidation (28).

Xanthine oxidase is an endogenous source of ROS that can produce free radicals, which inflicts liver injury. In the present study WPA and ST were used to inhibit XO activity. The obtained data revealed that XO activity was increased in TAA –induced necrosis (Fig. 4.), indicating its role in liver injury.

As a result of increased activity of XO we have obtained increased levels of O₂⁻ in groups treated by hepatotoxic agents. Both tungstate compounds caused decrease of O₂⁻ which was statistically significant, Fig. 4b.

An increase in hepatic malondialdehyde content, as index of oxidative liver damage, was detected in TAA treated rats, but it was not statistically different in comparison with control animals (Fig. 4c.).

Reduced glutathione (GSH) plays a vital role in cellular function, detoxifies toxic metabolites of drugs, and regulates gene expression, apoptosis and transmembrane transport of organic solutes. A decrease of GSH concentration which we observed in rats treated by hepatotoxic substances is the result of an effort by the tissue to counteract the effect of the ROS. As we expected we obtained significant increase of GSH in group pretreated with WPA and ST. Tunes et al. found that the biochemical signs triggered by TAA were prevented by DMSO administration (29). These data are also compatible with the studies from Bruck et al. (30). In our study, the most pronounced increasing were obtained for groups treated with both DMSO and investigated tungsten compounds, compared with GSH levels of WPA+T- or ST+T-treated groups. That undoubtedly confirmed the synergistic influence of DMSO on WPA and ST hepatoprotective effect.

Conclusion

DMSO alone exhibited hepatoprotective effect in animals treated with TAA. These results are in accordance with literature data which reported that antioxidants such as dimethylsulfoxide (DMSO) decreased TAA-induced liver damage (31). The necrosis score was significantly lower in the group pretreated with DMSO and tungstates, especially with ST. On the other hand, when DMSO was applied with WPA or ST, we detected statistically lower levels of all followed parameters of TAA-induced liver necrosis (AST, ALT and AP). Combined effects of DMSO- and tungstates-pretreatment on oxidative stress parameters and antioxidative defense status after administration of TAA, are evident. Results are expressed on activity of XO, level of O_2^- , malondialdehyde and GSH, as well. Synergistic effect is more pronounced for ST.

The present findings indicate that DMSO has a synergistic influence on tungstate, especially ST protective effects on liver cells and may provide further insight into therapeutic interventions against hepatotoxicants.

References

1. Pope MT. *Heteropoly and Isopoly Oxometalates*, Springer-Verlag, Berlin, 1983.
2. Delgado O, Dress A, Müller A, Pope MT. Polyoxometalates: A class of compounds with remarkable topology. In: Pope MT, Müller A. ed. *Polyoxometalates: From Platonic Solids to Anti-Retroviral Activity*, Kluwer Academic Publishers, Dordrecht, 1994.
3. Rhule J, Hill C, Judd D, Schinazi R. Polyoxometalates in medicine. *Chem Rev* 1998; 98: 327-357.
4. Pope MT, Muller A. *Polyoxometalates Chemistry, From topology via Self-Assembly to Applications*, Kluwer Academic Publishers, Dordrecht, 2001.
5. Mioč UB, Todorović MR, Davidović M, Colomban Ph, Holclajtner-Antunović I. *Solid State Ionics* 2005; 176: 2837.
6. Jelikić-Stankov M, Uskoković-Marković S, Holclajtner-Antunović I, Todorović M, Đurđević P. Compounds of Mo, V and W in biochemistry and their biomedical activity. *J Trace Elem Med Biol* 2007; 21: 8-16.
7. Catterall WA, Pedersen PL. *Biochem Biophys Res Commun*. Effects of phosphotungstic acid and silicotungstic acid on respiration and integrity of rat liver mitochondria. 1970; 38: 400-405.
8. Fessenden-Raden JM. Effect of silicotungstate on reduced diphosphopyridine nucleotide oxidation in submitochondrial particles. *J Biol Chem* 1971; 246: 6745-6749.
9. Achudume AC. Effect of dimethyl sulfoxide (DMSO) on carbon (CCl₄)-induced hepatotoxicity in mice. *Clin. Chem. Acta*, 1991; 200: 57-58.
10. Siegers CP. Antidotal effect of dimethyl sulfoxide against paracetamol-, brombenzene-, and thioacetamide-induced hepatotoxicity. *J Pharm Pharmacol* 1978; 30: 375-377.
11. Bryton CF. Dimethyl sulfoxide (DMSO): A review. *Cornell Vet*. 1986; 76: 61-90.
12. Lind RC, Begay CK, Gandolfi AJ. Hepatoprotection by Dimethyl Sulfoxide. *Toxicol Appl Pharmacol* 2000; 166: 145-150.
13. Sant GR. Intravesical 50% dimethyl sulfoxide (RIMSO-50) in treatment of interstitial cystitis. *Urology* 1987; 29(4, Suppl.): 17-21.
14. Rosenstein ED. Topical agents in the treatment of rheumatic disorders. *Rheum Dis Clin North Am* 1999; 25: 899-918.
15. Salim AS. Allopurinol and dimethyl sulfoxide improve treatment outcomes in smokers with peptic ulcer disease. *J Lab Clin Med* 1992; 119: 702-709.
16. Swanson BN. Medical use of dimethyl sulfoxide (DMSO). *Rev Clin Basic Pharm* 1985; 5: 1-33.
17. McCammon KA, Lentzner NA, Moriarty RP, Schellhammer PF. Intravesical dimethyl sulfoxide for primary amyloidosis of the bladder. *Urology* 1998; 52:1136-1138.

18. Ikeda Y, Long DM. Comparative effects of direct and indirect hydroxyl radical scavengers on traumatic brain oedema. *Acta Neurochir Suppl (Wien)* 1990; 51: 74–76.
19. Uskoković-Marković S, Milenković M, Topić A, Kotur-Stevuljević J, Stefanović A, Antić-Stanković J. Protective effects of tungstophosphoric acid and sodium tungstate on chemically induced liver necrosis in Wistar rats. *J Pharm Pharmaceut Sci* 2007; 10: 340-349.
20. Pawa S, Ali S. Liver necrosis and fulminant hepatic failure in rats: protection by oxyanionic form of tungsten. *Biochim Biophys Acta* 2004; 1688: 210–222.
21. Brauer G. *Handbuch der Präparativen Anorganischen Chemie*, Ferdinand Enke Verlag, Stuttgart, 1981.
22. De Ferreyra EC, Bernacchi AS, San Martin MF, Castro GD, Castro JA. Trifluopromazine late preventive effects on Carbon Tetrachloride- Induced Liver Necrosis. *Exp Mol Pathol* 1995; 62: 75-82.
23. Girotti MJ, Khan N, McLellan BA. Early measurement of systemic lipid peroxidation products in plasma of major blunt trauma patients. *J Trauma* 1991;31: 32-35.
24. Auclair C, Voisin E. Nitroblue tetrazolium reduction. In: Greenwald RA, ed. *CRC Handbook of Methods for Oxygen Radical research*. Boca Raton, Fla: CRC Press; 1985: 123-132.
25. Jollow DJ, Mitchell JR, Zampaglione N, Gillette JR. Bromobenzene-induced liver necrosis. Protective role of glutathione and evidence for 3,4-bromobenzene oxide as the hepatotoxic metabolite. *Pharmacology* 1974; 11: 151-169.
26. Stirpe F, Della Corte E. The regulation of rat liver xanthine oxidase. Conversion in vitro of the enzyme activity from dehydrogenase (type D) to oxydase (type O). *J Biol Chem* 1969; 244: 3855-3863.
27. Bradford MM. A rapid and sensitive method for the quantitation of the microgram quantities of protein utilizing the principle of protein-dye binding. *Analytical Biochemistry* 1976; 72: 248-254.
28. Reynold ES, Moslen MT. Free radicals damage in liver. In: Pryer WA. (Eds.), *Free radicals in biology*, Vol. 4., Academic Press, New York, 1980. pp. 49-94.
29. Tunes I, Munoz M, Villavicencio M, Medina F, de Prado EP, Espejo I et al. Hepato- and neurotoxicity induced by thioacetamide: Protective effects of melatonin and dimethylsulfoxide. *Pharm Res* 2005; 52 : 223–228.
30. Bruck R, Aeed H, Shirin H, Matas Z, Zaidel L, Avni Y, et al. Themhydroxyl radical scavengers dimethylsulfoxide and dimethylthiourea protect rats against thioacetamide-induced fulminant hepatic failure. *J Hepatol* 1999; 31: 27–38.
31. Kishioka T, Iida C, Fujii K, Nagae R, Onishi Y, Ichia I, Kojo S. Effect of dimethyl sulphoxide on oxidative stress, activation of mitogen activated protein kinase and necrosis caused by thioacetamide in the rat liver. *Europ J Pharm* 2007; 564: 190-195.

Pozitivan učinak dimetilsulfoksida na hepatoprotektivnu aktivnost volframata

**Snežana Uskoković-Marković¹, Marina Milenković²,
Aleksandra Topić³, Jelena Kotur-Stevuljević³, Aleksandra
Stefanović³, Jelena Antić-Stanković², Ivanka Holclajtner-
Antunović⁴**

¹Institut za analitičku hemiju,

²Institut za mikrobiologiju i imunologiju,

³Institut za medicinsku biohemiju,

Farmaceutski fakultet, Univerzitet u Beogradu,

Vojvode Stepe 450, Beograd 11 221, Srbija

⁴Fakultet za fizičku hemiju, Univerzitet u Beogradu,

Studentski trg 12-16, Beograd, Srbija

Kratak sadržaj

Volframati i polioksovolframati su decenijama poznati kao biološki aktivna jedinjenja. Kao nastavak prethodnog istraživanja hepatoprotektivnog efekta natrijum volframata (ST) i 12-volframfosforne kiseline (WPA), izveden je eksperiment na Wistar pacovima, koji su pretretirani sa ST i WPA tokom sedam nedelja a nakon tog perioda im je intraperitonealno ubrizgan tioacetamid (TAA) u cilju indukovanja akutne nekroze jetre. Ispitivan je uticaj dimetil sulfoksida (DMSO), koji je primenjivan *per os* u toku 3 konsekutivna dana pre indukcije hepatične nekroze. Efekti su evaluirani praćenjem aktivnosti serumskih enzima, parametara oksidativnog stresa, antioksidativnog odbrambenog markera, kao i histopatološkom analizom tkiva jetre. Dobijeni rezultati ukazuju da oralni pretretman pacova sa volframatima, pre svega ST, u kombinaciji sa DMSO, može biti koristan u prevenciji nekroze jetre indukovane tioacetamidom.

Ključne reči: Dimetilsulfoksid, volframati, nekroza jetre, pacovi
